

Original Research Article

Intradiscal Platelet-Rich Plasma Injection for Chronic Discogenic Low Back Pain: Preliminary Results from a Prospective Trial

David Levi, MD,* Scott Horn, DO,*
Sara Tyszko, PA,* Josh Levin, MD,†
Charles Hecht-Leavitt, MD,‡ and
Edward Walko, DO*

*APM Spine and Sports Physicians, Norfolk, Virginia;

†Stanford School of Medicine, Department of Orthopaedic Surgery, Redwood City, California; ‡MRI and CT Diagnostics, Virginia Beach, Virginia, USA

Correspondence to: David Levi, MD, APM Spine and Sports Physicians, 5665 Lowery Rd, Norfolk, VA, USA.
Tel: 757-422-2966; Fax: 757-422-4563; E-mail: levid@cox.net.

Conflict of interest: No authors have any conflict of interest.

Abstract

Background. Platelet-rich plasma (PRP) has been found to be effective for a variety of musculoskeletal conditions. The treatment of discogenic pain with PRP is under investigation.

Objective. To assess changes in pain and function in patients with discogenic low back pain after an intradiscal injection of PRP.

Study Design. Prospective trial.

Methods. Patients were diagnosed with discogenic low back pain by clinical means, imaging, and exclusion of other structures. Provocation discography was used in a minority of the patients. Patients underwent a single treatment of intradiscal injection of PRP at one or multiple levels.

Main Outcome Measures. Patients were considered a categorical success if they achieved at least 50% improvement in the visual analog score and 30% decrease in the Oswestry Disability Index at 1, 2, and 6 months post-treatment.

Results. 22 patients underwent intradiscal PRP. Nine patients underwent a single level injection, ten at 2 levels, two at 3 levels, and one at 5 levels. Categorical

success rates were as follows: 1 month: 3/22 = 14% (95% CI 0% to 28%), 2 months: 7/22 = 32% (95% CI 12% to 51%), 6 months: 9/19 = 47% (95% CI 25% to 70%).

Conclusion. This trial demonstrates encouraging preliminary 6 month findings, using strict categorical success criteria, for intradiscal PRP as a treatment for presumed discogenic low back pain. Randomized placebo controlled trials are needed to further evaluate the efficacy of this treatment.

Key Words. Disc; Intradiscal; Platelet-rich Plasma; PRP; Discogenic

Introduction

Low back pain is a very common cause of pain and disability. Although several structures within the spine have been identified as pain generators, the intervertebral disc is felt to account for 40% to 50% of chronic low back pain [1,2]. The most common conservative treatment options for discogenic back pain include activity restriction, medications, physical therapy, chiropractic treatment, and steroid injections. Many patients have an inadequate response to these conservative measures and progress to surgical treatment, either lumbar fusion or disc replacement.

Minor complications are common with lumbar fusion surgery. Severe complications are rare but do occur, with mortality rates ranging from 0.1% to 0.6% [3–11]. Beyond the issue of the complication rate is the question of the effectiveness of fusion or disc replacement procedure as a treatment for low back pain. The evidence for the superiority of fusion over conservative treatment, at this point, remains unclear [12–17]. In addition, the outcomes for lumbar disc replacement have not demonstrated superiority over fusion [18].

Prior interventional conservative treatments have been aimed at annular tear pathology, which is felt to be the anatomic source responsible for discogenic low back pain [19,20]. Attempts to alter the annular tear and associated neural structures with heat or radiofrequency energy have been disappointing [21,22]. More recently, Peng and colleagues investigated the use of methylene blue as a neurolytic agent within discs [23,24]. These investigators published two quality clinical studies

demonstrating the efficacy of intradiscal methylene blue. Unfortunately, further investigations have failed to produce their superior results [25–28].

Ultimately, the ideal treatment for pain induced by annular tears would be through direct healing of the tears themselves. Attempts are being directed toward this goal with research in areas such as stem cells and specific growth factor injections [29]. Another therapeutic agent promoting regeneration is platelet-rich plasma (PRP).

Platelet-rich plasma is obtained by preparing an autologous sample of blood with the use of a centrifuge, which concentrates the platelets and other blood components. PRP contains platelet concentration three to eight times that found in whole blood [29]. Along with the increased concentration of platelets, PRP contains higher levels of growth factors and cytokines, which stimulate tissue healing. The platelets themselves secrete growth factors needed for tissue repair such as epithelial growth factor (EGF), insulin-like growth factor (IGF-1), platelet-derived growth factor (PDGF), transforming growth factor (TGF- β), basic fibroblast growth factor (b-FGF), and vascular endothelial growth factor (VEGF) [29–31]. These growth factors increase collagen content, accelerate endothelial regeneration, and promote angiogenesis in many different types of tissues [31]. The concentration of growth factors parallels that of the increased concentration of platelets in PRP [31]. In addition to the healing properties of the growth factors themselves, they may also activate quiescent stem cells to further promote tissue repair [29].

In the last 5 years, the use of PRP has become very popular in the treatment of a myriad of musculoskeletal conditions. Animal and human research has demonstrated PRP efficacy for conditions requiring the repair of injured or degenerated collagen-based tissues such as tendon, ligament, and cartilage [29,32]. Good results have been reported in high-quality clinical studies in the common extensor tendon of the elbow [32], rotator cuff tendons [33], and knee articular cartilage [34].

More recently, work has been applied to the intervertebral disc. Theoretically, this may be more difficult as the disc is a complex and relatively avascular structure [35]. *in vitro* studies of animal and human disc cells have demonstrated positive effects of PRP. Growth factors released by PRP appear to reduce apoptosis [36]. Disc cells cultured with PRP demonstrate improved proteoglycan synthesis and annulus cell proliferation [37–39]. PRP also appears to inhibit the detrimental inflammatory effect of TNF- α and Interleukin-1 on human nucleus pulposus cells [40].

In vivo animal studies on experimentally injured discs also demonstrate a beneficial effect of PRP. These trials show a protective effect of PRP on disc degeneration compared to controls including a restoration of disc height and T2 signal on MRI [41–45]. No safety issues were seen [41–45], nor were there any mutagenic changes of the nucleus pulposus cells to indicate an increased risk of neoplasm [41].

A randomized placebo-controlled trial of intradiscal PRP in humans is currently under way [46]. The researchers are injecting PRP at the time of provocation discography. Patients demonstrating a painful response to disc pressurization are injected with a variable volume (1 to 2 mL) PRP (treatment group) or further contrast injection (control group). Data have been presented on 42 patients, with encouraging preliminary results [46].

The authors of the current study undertook a prospective trial to help determine the apparent effectiveness and safety of a single injection, of uniform volume, of PRP into one or more intervertebral discs for the treatment of presumed discogenic low back pain. Preliminary results are being presented.

Methods

The study was approved by an independent institutional review board: Sterling IRB, Trial No. 4143-001S. The participants were drawn from a pool of consecutive patients who had been referred internally from within the investigators' practice or externally from local primary care physicians, physiatrists, or spine surgeons. Patients paid out of pocket for the procedure, \$950 for one-level procedures, and \$1,150 for multilevel procedures. No external funding or other means of support was received for this trial.

To be eligible for inclusion, patients had to be older than 18 years of age; be able to consent; have back pain greater than leg pain with an intensity of at least 40 mm on a 0 to 100 mm visual analog scale; and, if female with child-bearing potential, to be on an acceptable form of contraception. Exclusion criteria are listed in Table 1.

To be selected for treatment, patients had to satisfy criteria for a presumptive discogenic pain and to have other sources of pain ruled out. The criteria for discogenic pain were one or more of the following:

- positive discography performed according to the guidelines of the International Spine Intervention society [47]; but discography was not a necessary criterion for selection;
- clinical features suggestive of discogenic pain, such as midline pain, pain upon rising from a seated position, or positive responses to centralization/peripheralization maneuvers [48–50];
- features suggestive of discogenic pain on magnetic resonance imaging, such as high-intensity zone, disc protrusion, decreased signal intensity on T2 imaging, or type 1 or type 2 Modic changes of an endplate [51–57].

Zygapophysial joint pain was ruled out if the patient's pain was not relieved by medial branch blocks or intra-articular blocks or had previously not been relieved by lumbar medial branch radiofrequency neurotomy. Sacroiliac joint pain was ruled out if the patient's pain was not relieved

Table 1 Exclusion criteria for a study of intradiscal injection of platelet-rich plasma for discogenic low back pain

- Non-discogenic source of back pain.
- Negative provocation discography.
- Active moderate to severe lumbar radiculopathy.
- Intradural disc herniation.
- Spinal fracture within past 6 months.
- Prior fusion at level considered to be the source of pain.
- Lumbar spine surgery within past 6 months.
- Steroid injection in spine within past 30 days.
- Any intradiscal injection other than contrast dye or anesthetic within past 30 days.
- AP diameter of spinal canal less than or equal to 5 mm at level to be treated.
- Inability to consent to procedure.
- Pregnant or breastfeeding.
- Severe uncontrolled medical condition.
- Active infection.
- Moderate to severe hepatic dysfunction.
- Severe psychological illness.
- Inflammatory arthritis.
- Malignancy within past 5 years except basal cell or squamous cell skin cancer.
- Coagulopathy preventing spinal injection.
- More than 30 mg morphine-equivalent per day of opioid use.
- A history of alcohol or drug abuse within past 5 years.
- Use of any investigational drug within past 30 days.
- A known allergy or sensitivity to citrate (used for processing PRP).
- Severe anaphylactic/anaphylactoid reaction to any medications used.
- Pending litigation involving subject's back pain.
- No insurance coverage for any subsequent tests or procedures.

by intra-articular blocks. Responses to blocks were considered negative if patient reported less than 50% relief of their pain.

Blocks of the zygapophysial joints were performed if the patient's pain was not midline [50]. Blocks of the sacroiliac joints were performed if the pain was not midline but also caudal to the L5 spinous process.

In patients whose clinical [48–50] and imaging [51–57] features suggested discogenic pain, blocks of the zygapophysial and sacroiliac joints were performed if the patient agreed to having these alternative sources of pain ruled out.

The PRP was prepared using a sterile technique using a Smartprep (Harvest Plymouth, MA, USA) procedure pack including the APC 30 blood draw and processing kit (for one or two discs to be injected) or APC 60 (for more than

two discs to be injected) at point of care in the pre-op area. For the APC 30 kit, 3 mL anticoagulant citrate dextrose formula A (ACD-A) were drawn into a 35 mL blood draw syringe. For the APC 60 kit, 6 mL of ACD-A were drawn into a 60 mL blood draw syringe. Venipuncture was performed after prepping the region with chlorhexidine and isopropyl alcohol. The syringe was disconnected from the tubing, and a sterile blunt needle with cap was connected. The syringe was labeled with the patient's name and date of birth. For the 30 mL process disposable, 1 mL ACD-A was injected into the plasma chamber. For the 60 mL process disposable, 2 mL ACD-A were injected into the plasma chamber. The previously drawn blood was then injected into the blood chamber.

Processing by centrifuge was performed with the Harvest SmartPrep 2 system (FDA cleared device) (Harvest, Plymouth, MA, USA). The process disposable and the balance weight were loaded into the centrifuge, and then the centrifuge was closed, locked, and started. The spin lasted approximately 14 minutes. The process disposable was then removed from the centrifuge. Using a sterile technique, approximately half of the platelet-poor plasma was removed using a syringe with spacer as provided in the kit. The remaining volume of platelets was re-suspended by aspiration into a syringe and injected back into the plasma chamber several times without removing the needle. When the suspension was complete, the PRP was aspirated into a sterile syringe that was labeled appropriately. The PRP concentrate was considered WBC-rich.

The disc level(s) to be injected were determined by one of two methods.

If the patient underwent discography performed using ISIS standards [47] within 6 months of the PRP injection, the positive levels determined during discography were chosen for injection with PRP. Prior provocation discography was, however, not required for the inclusion criteria. The rationale for this was based on the risk/benefit ratio. It was felt that the potential risk of discography [59] would outweigh the potential risk of injecting a seemingly benign substance into a non-painful disc. Therefore, in the absence of a prior discogram, the levels were determined clinically and with MRI findings suggestive of discogenic low back pain, including high-intensity zone, disc protrusion, decreased disc signal on T2 sequence, or type 1 or type 2 endplate Modic changes [51–57]. The general level of pain and tenderness on exam (upper, middle, or lower lumbar region) was also taken into account.

The procedure was performed by two of the investigators (DL and SH). Both are board certified in physical medicine and rehabilitation, experienced discographers, and fellowship trained in spine injections and serve as instructors for spinal injection procedures at the national level.

Patients were offered a sedative of 5 to 10 mg oral Valium or 0.5 to 1 mg Xanax to be taken 30 to

60 minutes prior to the procedure. Alternatively, patients were offered conscious sedation in the form of 2 to 6 mg Versed IV with the possible addition of 50 to 150 mg fentanyl IV. Continuous cardiac, pulse oximetry, and clinical monitoring were performed throughout the procedure.

Patients were placed in a prone position in an outpatient fluoroscopy suite. Strict sterile technique was observed. The lower back was cleansed with chlorhexadine and then betadine or alcohol and covered with a sterile drape. A standard posterolateral extrapedicular discogram technique was used under intermittent fluoroscopic imaging for each level previously determined to be a presumptive pain generator. The skin and superficial tissues were anesthetized with 2 to 5 mL of lidocaine 1%. The needle tip of a 22-gauge or 25-gauge needle with stylet, single needle technique, was directed into the disc nucleus. One mL of contrast solution consisting of 0.6 mL Omnipaque 240 or 300 contrast agent was injected to ensure an intranuclear flow pattern in AP and lateral views (Figure 1). Four-tenths of 1 mL of 40 mg/mL gentamicin for a total of 16 mg at a final concentration of 5 mg/mL was injected with the contrast for discitis prophylaxis. Lidocaine 4%, 0.5 mL, was injected for pain control. Then, 1.5 mL of previously prepared autologous PRP was injected into the disc. Thus, a total volume of 3 mL was injected into each of the presumed pain-generating discs during the treatment. In instances where the disc could not accommodate the full volume of PRP owing to high pressure (based on manual pressure estimation) or leakage into the epidural space, the clinician injected less than the 1.5 mL of the PRP, and this was recorded in the procedure note. At least 0.5 mL of the PRP was required to be injected into a disc to be considered a completed treatment. After the solution was

injected, the needle was removed. The antiseptic prep was cleansed from the patients' back and the drape removed. The patients then either ambulated with assistance or were transported via wheelchair to the recovery room.

Patients completed a follow-up visual analog score and Oswestry Disability Index [58] before treatment, and at 1 month, 2 months, and 6 months after the procedure [58]. These instruments of assessment were administered by one of the three co-authors (SL, SH, or ST).

Table 2 Demographic features of patients selected for treatment with intradiscal platelet-rich plasma

Male	10
Female	12
Age at procedure (years)	
Median	47.5
IQR	36 – 54
Employed	22
Unemployed	0
Insurance status	
Workers' Compensation	2
Private	19
Medicare	0
Legal	1
Duration of low back pain (months)	
Median	90
IQR	26 – 120

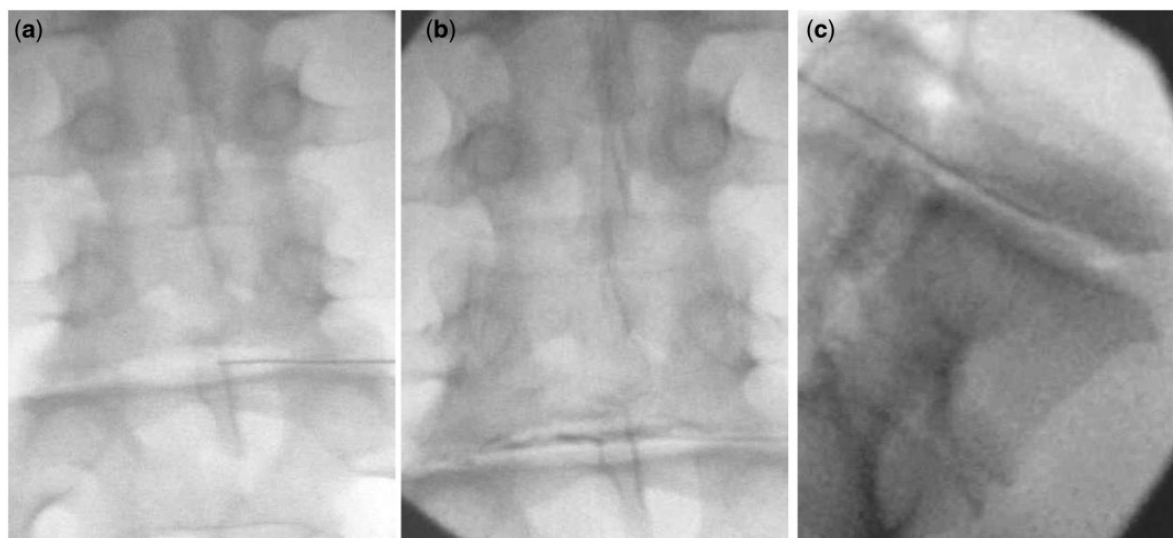


Figure 1 Fluoroscopy views of needle placement for an injection of platelet-rich plasma into an L5-S1 disc. (a) Antero-posterior view before injection of contrast medium. (b) Antero-posterior view after injection of contrast medium. (c) Lateral view.

Table 3 Diagnostic criteria satisfied by patients selected for treatment with intradiscal platelet-rich plasma

Features used for diagnosis of lumbar discogenic pain										
Patient	Other procedures				MRI features					Clinical
	IA	MBB	RFN	SIJ	Modic changes			Decreased T2 Signal	Protrusion	
					Type 1	Type 2	HIZ			
1	neg			neg		L5/S1	L4/5	L4/5	L4/5	no
2	neg				L5/S1			L4/5 L5/S1	L4/5 L5/S1	
3							L4/5 L5/S1	L4/5 L5/S1	L4/5 L5/S1	
4	pos	pos	neg					L2/3 L3/4 L4/5 L5/S1	L3/4 L4/5 L5/S1	
5							L4/5 L5/S1	L4/5 L5/S1	L5/S1	no
6							L4/5	L4/5		yes
7	pos	pos	neg			L5/S1		L5/S1	L5/S1	no
8	neg	neg		neg		L5/S1	L5/S1	L5/S1	L5/S1	
9	neg							L5/S1	L5/S1	
10				neg		L5/S1		L5/S1	L5/S1	no
11	pos	pos	neg	neg		L5/S1	L5/S1	L5/S1	L4/5 L5/S1	yes
12	pos	neg		neg				L4/5 L5/S1		no
13				neg		L5/S1		L3/4 L4/5 L5/S1	L5/S1	no
14	neg				L2/3	L4/5	L4/5	L1/2 L2/3 L3/4 L4/5 L5/S1	L3/4 L4/5	yes
15		neg						L3/4 L4/5	L3/4	no
16		neg						L4/5	L4/5	yes
17		neg					L4/5	L4/5 L5/S1	L4/5 L5/S1	no
18		neg				L3/4	L3/4	L2/3 L3/4 L4/5 L5/S1	L2/3 L3/4 L4/5 L5/S1	no
19					L5/S1		L5/S1	L5/S1	L5/S1	no
20					L2/3		L3/4 L4/5	L2/3 L3/4 L4/5		no
21	neg						L3/4 L4/5	L3/4 L4/5	L4/5	no
22	pos	neg			L4/5	L5/S1	L5/S1	L3/4 L4/5 L5/S1	L4/5 L5/S1	no

Z-joint: zygapophysial joint. SIJ: sacroiliac joint intra-articular block. (+): block positive. (-): block negative. IA: intra-articular. MBB: medial branch blocks. RF: no relief from radiofrequency neurotomy. Modic changes: (1) = type 1, (2) = type 2, mixed = type 1 and 2. HIZ: high-intensity zone.

Table 4 Segmental levels of discs in each patient treated with injections of platelet-rich plasma

Patient	Disc treated				
	L1/2	L2/3	L3/4	L4/5	L5/S1
1				■	
2				■	
3				■	
4				■	
5				■	
6				■	
7					■
8					■
9					■
10					■
11					■
12				■	■
13			■	■	■
14	■	■	■	■	■
15			■	■	■
16				■	■
17				■	■
18			■	■	■
19			■	■	■
30			■	■	■
21				■	■
22				■	■

A successful outcome was defined as 50% improvement in VAS accompanied by a 30% improvement in ODI.

Results

Table 2 records the demographic features of the patients treated. Table 3 shows the diagnostic features satisfied by each patient for inclusion in the study. Table 4 shows the segmental levels and the number of discs treated. All patients received a uniform volume of 1.5 mL of PRP. There were no instances of discitis or increased radicular symptoms and no neurologic or other complications.

No patients were lost to follow-up. All 22 patients completed the 2-month follow-up, and 19 patients reached 6-month follow-up at the time of publication. Individual VAS and ODI scores and percent changes, along with group median and interquartile range, are provided in Tables 5 and 6.

At 1-month follow-up, only 3 of the 22 patients (14%, with 95% confidence intervals [CIs] of 0% to 28%) satisfied the criteria for successful outcome (Table 7).

However, 36% achieved a 50% decrease in VAS independent of their ODI score.

At 2 months, seven patients (32%; 12% to 51%) had a successful outcome (Table 7), and 41% achieved a 50% decrease in VAS independent of their ODI score.

At 6 months, 9 of 19 patients had a successful outcome (47%; 25% to 70%) (Table 7). Results were the same for a 50% decrease in VAS alone.

Although no patient was lost to follow-up, a single subject (patient 5) who did not qualify as a categorical success at any follow-up time point did undergo a concurrent treatment. The patient underwent an epidural steroid injection (ESI) for a severe exacerbation after the 2 month data were recorded. One month following the ESI (3 months after the PRP injection), he underwent a second PRP injection. His 6 month data, provided in Table 6, remained below the ODI success threshold of 30% improvement. Therefore, the patient was considered a categorical failure regardless of the concurrent treatment. In determination of the group median and interquartile range, however, his 6 month data were not used. Rather, the 2 month follow-up

data were carried forward and used for the 6 month follow-up.

Discussion

Although the early results of this trial are poor, the preliminary 6 month results are encouraging. At the 6 month follow-up after a single intradiscal injection of PRP, 47% of patients reported at least a 50% improvement in conjunction with a 30% improvement in their ODI score. Although these are not outstanding results, the criteria used for defining success were conservative. The 50% pain improvement was chosen based on what most patients considered “much improved” [60]. The criterion of 30% improvement in the ODI score was selected based on a consensus on minimal important change for low back pain [61]. Many investigators use more liberal criteria for clinically important change for chronic low back pain of 20mm on the VAS [62]. In the current study, at the 6 month follow-up, 12 of 19 patients, or 63% (95% CI 42% to 85%), achieved an improvement on the VAS of at least 20 mm.

The poor early results in this study may reflect the mechanism of action of PRP and the time required for the treatment effect to occur. Multiple studies using PRP for other orthopedic conditions have demonstrated similar lengths of time for significant improvement [32,63,64]. The exact process by which PRP may facilitate healing has been postulated but is not clearly understood [65–69]. Therefore, the time frame for the theoretical beneficial effect to the disc to occur is also unknown but may be between 2 and 6 months based on the findings of the present trial.

It is possible that the regenerative effect of PRP on the intervertebral disc could have been enhanced further using a different injectate protocol. In the current study, prior to injecting the PRP, 0.6mL of contrast, 0.4 mL of gentamicin 40mg/mL, and 0.5mL of lidocaine 4% were injected for confirmation of needle position, discitis prophylaxis, and pain control. Prior studies have demonstrated a negative effect of anesthetics, antibiotics (including gentamicin), and contrast on nuclear cell synthesis in culture [70–73]. The addition of these substances may have had an adverse effect on our results. Additionally, a different preparation of PRP may have been more beneficial.

Table 5 Scores for back pain on visual analog scale (VAS) and Oswestry Disability Index (ODI) of patients treated with intradiscal platelet-rich plasma, at inception, and at 1, 2, and 6 months after treatment

Patient number	VAS				ODI			
	Inception	1M	2M	6M	Inception	1M	2M	6M
1	88	79	78	48	30	32	34	28
2	55	62	48	60	33	26	22	30
3	65	67	83	0	24	38	36	10
4	70	28	50	5	12	14	14	6
5	64	26	66	66*	17	14.5	20	20*
6	54	34	61	22	26	20	18	16
7	75	66	62	73	40	36	34	40
8	68	55	35	31	44	42	40	22
9	65	19	70	17	30	20	36	12
10	52	70	7	64	40	54	10	64
11	48	31	20	8	22	16	14	4
12	61	22	26	65	44	42	38	44
13	64	19	0	80	40	18	14	44
14	75	64	57	32	34	28	24	10
15	61	71	41	74	31	40	29	29
16	77	59	38	53	38	34	14	30
17	86	65	72	62	26	30	23	14
18	99	19	2	8	44	27	17	22
19	65	66	32	19	30	9	8	2
20	50	21	22		10	14	26	
21	51	30	14		32	24	16	
22	58	41	42		34	30	26	
Median	64.5	48	41.5	48	31.5	27.5	22.5	22
IQR	55-75	26-66	22-62	17-65	26-40	18-36	34-14	10-30

IQR: interquartile range.

*The VAS and ODI scores at 6 months for patient 5 were carried forward from 2 months because this patient underwent concurrent treatment between 2 and 6 month follow-ups.

Table 6 Percentage changes in back pain scores on visual analog scale (VAS) and Oswestry Disability Index (ODI) of patients treated with intradiscal platelet-rich plasma, at 1, 2, and 6 months after treatment

Patient	Percent changes in scores from inception					
	Back pain			ODI		
	1M	2M	6M	1M	2M	6M
1	10	10	45	-7	-13	7
2	-13	13	-9	21	33	9
3	-3	-28	100	-58	-50	58
4	60	29	93	-16	-16	50
5	59	-3	-3	12	-18	-18
6	37	-13	59	23	31	38
7	12	17	3	10	15	0
8	19	49	54	5	9	50
9	70	-8	74	33	-17	60
10	-35	87	-23	-35	75	-60
11	35	58	83	27	36	82
12	64	57	-7	5	14	0
13	70	100	-25	55	65	-10
14	15	24	55	18	29	71
15	16	33	-20	-29	10	10
16	23	51	31	11	63	21
17	24	16	28	-15	12	46
18	81	98	92	39	61	50
19	-2	51	71	70	73	93
20	58	56		-40	-62	
21	41	73		25	50	
22	29	29		12	24	
Median	30	36	37	8	19	29
IQR	13 to 60	14 to 57	-5 to 73	-13 to 25	8 to 47	4 to 54

IQR: interquartile range. A positive change indicates improvement; a negative change indicates pain (VAS) or function (ODI) worsened.

Specifically, the system used in this study produces a relatively high hematocrit. Studies do indicate that red blood cells may have a deleterious effect not only on platelet function by alteration of the pH [67,74] but also on chondrocyte survival [75]. This is an area for future research consideration.

Our findings are similar to the results presented at several scientific meetings. Lutz and colleagues have presented preliminary data on a randomized, placebo-controlled trial of 42 patients with an 8 week crossover [46]. The 8 week between-group data showed modest but categorical results demonstrating a much higher satisfaction rate for the PRP group over control using the North American Spine Society patient satisfaction questionnaire. One year, within-group data demonstrated significant, but modest, pain improvement. Based on the apparent improvement time frame seen in the current study (between 2 and 6 months), Lutz et al. may have failed to allow

ample time for a treatment effect compared to placebo as they used an 8 week crossover protocol [46]. The PRP injection in the Lutz et al. study was performed at the time of discography immediately following a positive determination. This protocol did not allow a uniform volume of PRP to be injected, which raises concerns that an inadequate treatment volume was delivered. This is in contrast to the current study, in which a uniform volume of 1.5 mL PRP was delivered to each disc. Both the current trial and Lutz et al. study used a red blood cell-rich and leukocyte-rich PRP formulation.

Akeda and colleagues injected six patients with a uniform volume of 2 mL leukocyte-poor and red blood cell-poor PRP releasate (substance isolated from activated PRP) at discogram-positive levels [76]. The benefit seen in their small group of patients was exceptional: mean pain scores decreased from 7.1 to 1.8 on a numeric rating scale (NRS) by 1 month and were sustained at 6 months [76].

Table 7 Number and proportions (95% confidence intervals) of patients who reported the combinations of categorical changes indicated in back pain scores on visual analog scale (VAS) and Oswestry Disability Index (ODI) after treatment with intradiscal platelet-rich plasma

Follow-up	Outcomes				ODI
	Back pain (VAS)			Worse	
	100%	>50%	<50%		
1 month		3		1	>30%
		14% (0-28)		5% (0-13)	
		2	8	1	<30%
		9% (0-21)	36% (16-57)	5% (0-13)	
2 months		6	2	1	>30%
	1	27% (9-46)	9% (0-21)	5% (0-13)	
		1	5		<30%
		5% (0-13)	23% (5-40)		
6 months		8	1		>30%
	1	42% (20-64)	6% (0-15)		
			3	3	<30%
			17% (0-32)	17% (0-32)	
		1	2	worse	
		6% (0-15)	11% (0-24)		

Regions highlighted in bold indicate numbers and proportions of patients who satisfied the combined criteria of 50% improvement in VAS and 30% improvement in ODI score.

Their protocol differed from that of the present study by the PRP formulation but was similar in that the PRP was not injected at the time of discography, allowing for a larger volume of PRP injectate. The time frame of improvement was also much earlier than in the present trial.

There are several limitations in this trial. The most significant issue is the diagnostic criteria for the intradiscal PRP treatment. The patients in this study were presumed to have discogenic pain based on clinical and imaging features and the exclusion of other likely sources of low back pain. Most did not undergo provocation discography, a diagnostic procedure that is often performed pre-operatively prior to lumbar fusion to help determine which discs are the source of the patient's pain. The decision to forgo discography as an inclusion criterion was based on multiple factors. Although performing an intradiscal PRP injection at the time of discography seems most practical, the volume of contrast during this diagnostic test may reach 3 mL if performed in accordance with ISIS guidelines [47]. This may leave little to no residual volume capacity to accommodate a presumed adequate PRP volume for treatment. Secondly, in accordance with ISIS guidelines [47], discography requires at least one negative control disc. Discography is invasive and has the potential for negative effects, including those that may have future clinical relevance [59]. Therefore, performing discography in

accordance with ISIS guidelines requires needle puncture with potential harm to a previously unaffected disc. As PRP is a minimally processed autologous substance and very unlikely to have any detrimental effects [29,31,41,42], the authors felt that the potential adverse effects of intradiscal PRP were likely no greater than those of discography. Therefore, subjecting patients to discography (including injecting a normal control level) in order to determine which discs are symptomatic adds an additional invasive procedure with disc puncture that is not warranted if discography is being utilized only for qualification of an intradiscal PRP injection. The authors' position, in summary, was that PRP at the time of discography would not provide ample volume for the PRP, and performing a separate discography procedure solely for determining the candidacy and level for the PRP injection could not be justified.

Without discography as a patient selection criterion in this trial, significant bias does exist. The authors used findings on history, physical examination, and imaging studies that did have some correlation with positive discography but were certainly limited in diagnostic value [48-57].

A further limitation of our patient selection protocol was the non-standardization of z-joint and SIJ blocks to rule

out these structures as the primary source of pain. The authors followed general guidelines of pain location for this determination [48,50]. However, clinical and imaging findings felt to be more consistent with a discogenic source [48–57] were also considered in the determination to perform z-joint or SIJ blocks. In situations in which the investigators felt a non-disc source of pain was very unlikely, patient preference was also considered in the decision to perform the blocks. This element of the protocol clearly introduces bias, as patients without discogenic pain may have undergone the intradiscal treatment.

The authors concede that many of the discs injected may not have been pain-producing discs. In addition, several of the patients may not have had a discogenic source of pain. However, including patients without discogenic pain would have biased the outcomes of treatment unfavorably, and the actual effectiveness of PRP for discogenic back pain may be greater than encountered in the present trial.

This study did not use a control group because of the significantly greater complexity and cost of performing a controlled trial. However, without a control group, non-specific treatment effects and natural history cannot be excluded as explanations for some of the successes.

Our definition of success may also be viewed as a trial limitation. The authors chose a 50% decrease in pain accompanied by a 30% improvement in function [60,61]. This may be viewed by some as overly conservative. However, as this is a novel and somewhat controversial treatment, we felt the stricter criteria of success would be more appropriate.

Conclusion

This trial demonstrates encouraging preliminary 6 month findings for intradiscal PRP as a treatment for presumed discogenic low back pain. Randomized placebo-controlled trials are needed to further evaluate the efficacy of this treatment.

Acknowledgments

The authors wish to express their gratitude to the editorial staff for their guidance in improving this manuscript.

References

- 1 Schwarzer A, Aprill C, Derby R, et al. The prevalence and clinical features of internal disc disruption in patients with chronic low back pain. *Spine* 1995; 20:1878–83.
- 2 DePalma MJ, Ketchum JM, Saullo T. What is the source of chronic low back pain and does age play a role? *Pain Med* 2011;12(2):224–33.
- 3 Turner JA, Ersek M, Herron L, et al. Patient outcomes after lumbar spinal fusions. *JAMA* 1992;268 (7):907–11. Review.
- 4 Deyo RA, Cherkin DC, Loeser JD, Bigos SJ, Ciol MA. Morbidity and mortality in association with operations on the lumbar spine. The influence of age, diagnosis, and procedure. *J Bone Joint Surg Am* 1992;74(4):536–43.
- 5 Ciol MA, Deyo RA, Howell E, Kreif S. An assessment of surgery for spinal stenosis: Time trends, geographic variations, complications, and reoperations. *J Am Geriatr Soc* 1996;44(3):285–90.
- 6 Deyo RA, Mirza SK, Martin BI, et al. Trends, major medical complications, and charges associated with surgery for lumbar spinal stenosis in older adults. *JAMA* 2010;303(13):1259–65.
- 7 Smith JS, Saulee D, Chen CJ, et al. Rates and causes of mortality associated with spine surgery based on 108,419 procedures: A review of the Scoliosis Research Society Morbidity and Mortality Database. *Spine* 2012;37(23):1975–82.
- 8 Rajaei SS, Bae HW, Kanim LE, Delamarter RB. Spinal fusion in the United States: Analysis of trends from 1998 to 2008. *Spine* 2012;37(1):67–76.
- 9 Mirza SK, Deyo RA, HEagerty PJ, et al. Towards standardized measurement of adverse events in spine surgery: Conceptual model and pilot evaluation. *BMC Musculoskeletal Disord* 2006;7: 53
- 10 Mannion AF, Fekete TF, O’Riordan D, et al. The assessment of complications after spine surgery: Time for a paradigm shift? *Spine J* 2013;13(6):615–24.
- 11 Mannion AF, Mutter UM, Fekete FT, et al. The bothersomeness of patient self-rated “complications” reported 1 year after spine surgery. *Eur Spine J* 2012;21(8):1625–32.
- 12 Fritzell P, Hagg O, Wessberg P, Nordwall A. The Swedish Lumbar Spine Study Group. Volvo award winner in clinical studies: Lumbar fusion versus non-surgical treatment for chronic low back pain. A multicenter randomized controlled trial from the Swedish Lumbar Spine Study Group. *Spine* 2001; 23:2521–34.
- 13 Fairbank J, Frost H, Wilson-MacDonald J, et al. Randomised controlled trial to compare surgical stabilisation of the lumbar spine with an intensive rehabilitation programme for patients with chronic low back pain: The MRC spine stabilisation trial. *Br Med J* 2005;330:1233–9.

Preliminary Results from a Prospective Trial

- 14 Hanley EN, David SM. Lumbar arthodesis for the treatment of back pain. *J Bone Joint Surg Am* 1999;81:716–30.
- 15 Brox JI, Sorensen R, Friis A, et al. Randomized clinical trial of lumbar instrumented fusion and cognitive intervention and exercises in patients with chronic low back pain and disc degeneration. *Spine* 2003;28(17):1913–21.
- 16 Brox JI, Reikeras O, Nygaard O, et al. Lumbar instrumented fusion compared with cognitive intervention and exercises in patients with chronic back pain after previous surgery for disc herniation: A prospective randomized controlled study. *Pain* 2006;122(1-2):145–55.
- 17 Carragee EJ, Cheng I. Minimum acceptable outcomes after lumbar spinal fusion. *Spine J* 2010;10(4):313–20.
- 18 Wei J, Song Y, Sun L, Lv C. Comparison of artificial total disc replacement versus fusion for lumbar degenerative disc disease: A meta-analysis of randomized controlled trials. *Int Orthop* 2013;37(7):1315–25.
- 19 Peng B, Wu W, Hou S, et al. The pathogenesis of discogenic low back pain. *J Bone Joint Surg Br* 2005;87:62–7.
- 20 Coppes MH, Marani E, Thomeer RT, Groen GJ. Innervation of “painful” lumbar discs. *Spine* 1997;22:2342–9.
- 21 Freeman BJ, Fraser RD, Cain CM, Hall DJ, Chapple DC. A randomized, double-blind, controlled trial: Intradiscal electrothermal therapy versus placebo for the treatment of chronic discogenic low back pain. *Spine* 2005;30:2369–77.
- 22 Barendse G, van den Berg S, Kessels A, Weber W, van Kleef M. Randomized controlled trial of percutaneous intradiscal radiofrequency thermocoagulation for chronic discogenic back pain. *Spine* 2001;26:287–92.
- 23 Peng B, Zhang Y, Hou S, Wu W, Fu X. Intradiscal methylene blue injection for the treatment of chronic discogenic low back pain. *Eur Spine J* 2007;16:33–8.
- 24 Peng B, Pang X, Wu Y, Zhao C, Song X. A randomized placebo-controlled trial of intradiscal methylene blue injection for the treatment of chronic discogenic low back pain. *Pain* 2010;149:124–9.
- 25 Bogduk N. Preliminary results from intradiscal methylene blue trial. Presented at International Spine Intervention Society Meeting. Chicago, IL; 2011.
- 26 Levi DS, Horn S, Walko E. Intradiscal Methylene blue treatment for discogenic low back pain. *PM R* 2014;6:1030–7.
- 27 Gupta G, Radhakrishna M, Chankowsky J, Asenjo JF. Methylene blue in the treatment of discogenic low back pain. *Pain Physician* 2012;15(4):333–8.
- 28 Kim SH, Ahn SH, Cho YW, Lee DG. Effect of intradiscal methylene blue injection for the chronic discogenic low back pain: One year prospective follow-up study. *Ann Rehabil Med* 2012;36(5):657–64.
- 29 Nguyen RT, Borg-Stein J, Mcinnis K. Application of platelet-rich plasma in musculoskeletal and sports medicine: An evidence based approach. *PM R* 2011;3:226–50.
- 30 Molloy T, Wang Y, Murrell G. The roles of growth factors in tendon and ligament healing. *Sports Med* 2003;33:381–94.
- 31 Podd D. Platelet-rich plasma therapy: Origins and applications investigated. *JAAPA* 2012; 25(6):44–9.
- 32 Peerbooms JC, Sluimer J, Bruijn DJ, Gosens T. Positive effect of an autologous platelet concentrate in lateral epicondylitis in a double-blind randomized controlled trial: Platelet-rich plasma versus corticosteroid injection with a 1-year follow-up. *Am J Sports Med* 2010;38:255–62.
- 33 Everts PA, Devilee RJ, Brown Mahoney C, et al. Exogenous application of platelet-leukocyte gel during open subacromial decompression contributes to improved patient outcome. A prospective randomized double-blind study. *Eur Surg Res* 2008;40(2):203–10.
- 34 Kon E, Buda R, Filardo G, et al. Platelet-rich plasma: Intra-articular knee injections produced favorable results on degenerative cartilage lesions. *Knee Surg Sports Traumatol Arthrosc* 2010;18(4):472–9.
- 35 Bogduk N. *Clinical Anatomy of the Lumbar Spine and Sacrum*, 3rd edition. Edinburgh: Churchill Livingstone; 2001: 22–23.
- 36 Gruber H, Norton J, Hanley N. Anti-apoptotic effects of IGF-1 and PDGF on human intervertebral disc cells in vitro. *Spine* 25:2153–7.
- 37 Akeda K, An HS, Pichika R, et al. Platelet-rich plasma (PRP) stimulates the extracellular matrix metabolism of porcine nucleus pulposus and annulus fibrosis cells cultured in alginate beads. *Spine* 2006; 31:959–66.
- 38 Pirvu TN, Schroeder JE, Peroglio M, et al. Platelet-rich plasma induces annulus fibrosus cell proliferation and matrix production. *Eur Spine J* 2014;23(4):745–53.

- 39 Chen WH, Lo WC, Lee JJ, et al. Tissue-engineered intervertebral disc and chondrogenesis using human nucleus pulposus regulated through TGF-beta1 in platelet-rich plasma. *J Cell Physiol* 2006;209:744–54.
- 40 Kim HJ, Yeom JS, Koh YG, et al. Anti-inflammatory effect of platelet-rich plasma on nucleus pulposus cells with response of TNF- α and IL-1. *J Orthop Res* 2014;32(4):551–6.
- 41 Nagae M, Ikeda T, Mikami Y, et al. Intervertebral disc regeneration using platelet-rich plasma and biodegradable gelatin hydrogel microspheres. *Tissue Eng* 2007;11:147–58.
- 42 Sawamura K, Ikeda T, Nagae M, et al. Characterization of in vivo effects of platelet-rich plasma and biodegradable gelatin hydrogel microspheres on degenerated intervertebral discs. *Tissue Eng Part A* 2009;12:3719–27.
- 43 Obata S, Akeda K, Imanishi T, et al. Effect of autologous platelet-rich plasma-releasate on intervertebral disc degeneration in the rabbit annular puncture model: A preclinical study. *Arthritis Res Ther* 2012;14:R241
- 44 Gui K, Ren W, Yu Y, et al. Inhibitory effects of platelet-rich plasma on intervertebral disc degeneration: A preclinical study in a rabbit model. *Med Sci Monit* 2015;21:1368–75.
- 45 Gullung GB1, Woodall JW, Tucci MA, et al. Platelet-rich plasma effects on degenerative disc disease: Analysis of histology and imaging in an animal model. *Evid Based Spine Care J* 2011;2(4):13–8.
- 46 Tuakli-Wosornu YA, Terry A, Gribbin C, et al. Lumbar intradiscal platelet rich plasma injections: A prospective, double-blinded randomized controlled study. Presented at International Spine Intervention Society Annual Meeting. Orlando, FL; 2014.
- 47 Bogduk N. Practice Guidelines for Spinal Diagnostic and Treatment Protocol, 2nd edition. San Francisco: International Spine Intervention Society; 2013;420–58.
- 48 Young S, Aprill CN, Laslett M. Correlation of clinical examination characteristics with three sources of chronic low back pain. *Spine J* 2003;3:460–5.
- 49 Laslett M, Oberg B, Aprill CN, McDonald B. Centralization as a predictor of provocation discography results in chronic low back pain, and the influence of disability and distress on diagnostic power. *Spine J* 2005;5(4):370–80.
- 50 DePalma MJ, Ketchum JM, Trussell BS, Saullo TR, Slipman CW. Does the location of low back pain predict its source? *PM R* 2011;3(1):33–9.
- 51 Aprill C, Bogduk N. High-intensity zone: A diagnostic sign of painful lumbar disc on magnetic resonance imaging. *Br J Radiol* 1992;65:361–9.
- 52 Peng B, Hou S, Wu W, Zhang C, Yang Y. The pathogenesis and clinical significance of a high-intensity zone (HIZ) of lumbar intervertebral disc on MR imaging in the patient with discogenic low back pain. *Eur Spine J* 2006;15(5):583–7.
- 53 Weishaupt D, Zanetti M, Hodler J, et al. Painful lumbar disk derangement: Relevance of endplate abnormalities at MR imaging. *Radiology* 2001;218:420–7.
- 54 Thompson KJ, Dagher AP, Eckel TS, Clark M, Reinig JW. Modic changes on MR images as studied with provocative diskography: Clinical relevance—a retrospective study of 2457 disks. *Radiology* 2009;250(3):849–55.
- 55 O’Neill C, Kurgansky M, Kaiser J, Lau W. Accuracy of MRI for diagnosis of discogenic pain. *Pain Physician* 2008;11:311–26.
- 56 Kang CH, Kim YH, Lee SH, et al. Can magnetic resonance imaging accurately predict concordant pain provocation during provocative disc injection? *Skeletal Radiol* 2009;38(9):877–85.
- 57 Bogduk N, Aprill CN, Derby R. Lumbar discogenic pain: State-of-the-art review. *Pain Med* 2013;14:813–36.
- 58 Fairbank JC, Couper J, Davies JB, O’Brien JP. The Oswestry low back pain disability questionnaire. *Physiotherapy* 1980;66:271–3.
- 59 Carragee E, Don A, Hurwitz E, et al. Does discography cause accelerated progression of degeneration changes in the lumbar disc. *Spine* 2009;34:2338–45.
- 60 Farrar JT, Young JP, La Moreaux L, Werth JL, Poole M. Clinical importance of changes in chronic pain intensity measured on an 11-point numerical pain rating scale. *Pain* 2001;94:149–58.
- 61 Ostelo RW, Deyo RA, Stratford P, et al. Interpreting change scores for pain and functional status in low back pain: Towards international consensus regarding minimal important change. *Spine* 2008;33(1):90–4.
- 62 Hägg O, Fritzell P, Nordwall A. Swedish Lumbar Spine Study Group. The clinical importance of changes in outcome scores after treatment for chronic low back pain. *Eur Spine J* 2003;12(1):12–20.
- 63 Kon E, Mandelbaum B, Buda R, et al. Platelet-rich plasma intra-articular injection versus hyaluronic acid viscosupplementation as treatments for cartilage

Preliminary Results from a Prospective Trial

- pathology: From early degeneration to osteoarthritis. *Arthroscopy* 2011;27(11):1490–501.
- 64 Spaková T, Rosocha J, Lacko M, Harvanová D, Gharaibeh A. Treatment of knee joint osteoarthritis with autologous platelet-rich plasma in comparison with hyaluronic acid. *Am J Phys Med Rehab* 2012;91(5):411–7.
- 65 Smyth NA, Murawski CD, Fortier LA, Cole BJ, Kennedy JG. Platelet rich plasma in the pathologic processes of cartilage: Review of basic science evidence. *Arthroscopy* 2013;29(8):1399–409.
- 66 Mishra A, Pavelko T. Treatment of chronic elbow tendinosis with buffered platelet-rich plasma. *Am J Sports Med* 2006;33(11):1774–8.
- 67 Braun HJ, Kim HJ, Chu CR, Dragoo JL. The effect of platelet-rich plasma formulations and blood products on human synoviocytes: Implications for intra-articular injury and therapy. *Am J Sports Med* 2014;42(5):1204–10.
- 68 Mishra A, Tummala P, King A, et al. Buffered platelet-rich plasma enhances mesenchymal stem cell proliferation and chondrogenic differentiation. *Tissue Eng Part C Methods* 2009;15(3):431–5
- 69 Mishra AK, Skrepnik NV, Edwards SG, et al. Efficacy of platelet-rich plasma for chronic tennis elbow: A double-blind, prospective, multicenter, randomized controlled trial of 230 patients. *Am J Sports Med* 2014;42(2):463–71.
- 70 Eder C, Pinsger A, Schildboeck S, et al. Influence of intradiscal medication on nucleus pulposus cells. *Spine J* 2013;13(11):1556–62.
- 71 Chee AV, Ren J, Lenart BA, et al. Cytotoxicity of local anesthetics and nonionic contrast agents on bovine intervertebral disc cells cultured in a three-dimensional culture system. *Spine J* 2014;14(3):491–8.
- 72 Hoelscher GL, Gruber HE, Coldham G, Grigsby JH, Hanley EN Jr. Effects of very high antibiotic concentrations on human intervertebral disc cell proliferation, viability, and metabolism in vitro. *Spine* 2000;25(15):1871–7.
- 73 Iwasaki K, Sudo H, Yamada K, Ito M, Iwasaki N. Cytotoxic effects of the radiocontrast agent iotrolan and anesthetic agents bupivacaine and lidocaine in three-dimensional cultures of human intervertebral disc nucleus pulposus cells: Identification of the apoptotic pathways. *PLoS One* 2014;9(3):e92442
- 74 Liu Y, Kalén A, Risto O, Wahlström O. Fibroblast proliferation due to exposure to a platelet concentrate in vitro is pH dependent. *Wound Repair Regen* 2002;10(5):336–40.
- 75 Hooiveld M, Roosendaal G, Wenting M, et al. Short-term exposure of cartilage to blood results in chondrocyte apoptosis. *Am J Pathol* 2003;162(3):943–51.
- 76 Akeda K, Imanishi T, Ohishi K, et al. Intradiscal injection of autologous platelet-rich-plasma for the treatment of lumbar disc degeneration-preliminary prospective clinical trial for discogenic low back pain patients. Presented at Orthopaedic Research Society Annual Meeting. San Francisco; 2012. Poster No. 2194.